

# Medical imaging fusion applications: An overview

Constantinos S. Pattichis<sup>1,2</sup>, Marios S. Pattichis<sup>2</sup>, Evangelia Micheli-Tzanakou<sup>3</sup>

<sup>1</sup>Department of Computer Science, University of Cyprus,  
Kallipoleos 75, P.O. Box 20537, CY1678 Nicosia, Cyprus email: [pattichi@ucy.ac.cy](mailto:pattichi@ucy.ac.cy)

<sup>2</sup>Department of Electrical and Computer Engineering, University of New Mexico,  
Albuquerque, NM 87131-1356, USA email: [pattichis@eece.unm.edu](mailto:pattichis@eece.unm.edu)

<sup>3</sup>Department of Biomedical Engineering, Rutgers University,  
617 Bowser Rd., Piscataway, NJ 08855, USA email: [etzanako@biomed.rutgers.edu](mailto:etzanako@biomed.rutgers.edu)

## Abstract

*Computer aided fusion of multi modality medical images provides a very promising diagnostic tool with numerous clinical applications. The objective of this paper is to present an overview of medical imaging fusion techniques with an emphasis on the use of neural network algorithms. Case studies derived from oncology (data level fusion), microscopy and ultrasound imaging (feature level and decision level fusion), and lesion placement in pallidotomy (data level fusion) are presented. It is anticipated that these tools will help the physician towards a more realistic and quantitative, assessment of disease.*

## I. Introduction

The overall objective of Computer Aided Diagnostic (CAD) systems is to enable the early diagnosis, disease monitoring, and better treatment. The advantages of CAD systems can be summarized as follows: *Standardization.* Diagnoses obtained from different laboratories using similar criteria can be verified. *Sensitivity.* Findings on a particular subject may be compared with a database of normal values and/or a decision can be made by a CAD system deciding whether or not an abnormality exists. *Specificity.* Findings may be compared with databases for various diseases and/or a decision can be made by the CAD system with respect to the type of abnormality. *Equivalence.* Results from a series of examinations of the same patient may be compared to decide whether there is evidence of disease progression or of response to treatment. In addition, the findings of different CAD systems can be compared to determine which are more sensitive and specific. *Efficacy.* The results of different treatments can be more properly evaluated. Medical imaging provides vital information for CAD systems.

The objective of this paper is to present a snapshot of medical imaging fusion techniques and how these techniques can be integrated in CAD systems.

According to Barillot et al. [1] data fusion in medical imaging "facilitates a better use of 3-D image data by providing methods for the fusion of data from multiple modalities e.g., multimodal registration and fusion between anatomical and functional data, the fusion of data from different patients or with a priori knowledge (models and/or atlases) and the recognition of complex anatomical structures and their symbolic identifications, when they are not explicitly described by the image contents." Unfortunately, in the medical imaging community, there is a lack of terms of reference and definitions for the exact meaning of data fusion in medical imaging.

In contrast, in the remote sensing community there is a consensus among different working groups, that [2,3]: "data fusion is a formal framework in which are expressed means and tools for the alliance of data originating from different sources. It aims at obtaining information of greater quality; where the exact definition of "greater quality" will depend upon the application." Emphasis is given in the words *framework* and not the tools, as well as on *quality* where the resulting information is more satisfactory for the "customer/user" when performing the fusion process than without it.

For the remote sensing community, data fusion techniques can be classified under the following three categories [4]: (i) Data level fusion, implying techniques that aim at the simple combination of the raw data from all the sensors taken into consideration; (ii) Feature level fusion, implying techniques for the extraction, combination and classification of feature vectors from all the considered sensors; (iii) Decision level fusion, implying techniques which aim at the combination of the outputs of the classifications achieved on each single source.

In this paper, a very brief review of data fusion in medical imaging is given. In the next section, the results of a literature search on data fusion in medical imaging are presented, as well as a snapshot of selected applications. In section III, case studies of a modular neural network system for the analysis of nuclei in histopathological sections, a multi-feature multi-classifier system for the classification of atherosclerotic carotid plaques, and a neural network system for the analysis of physiological data for lesion placement in pallidotomy are presented. Finally, in section IV concluding remarks are presented. This paper shares content with another review paper on adaptive neural network systems in medical imaging published also in these proceedings [5].

## II. Literature review and a snapshot of selected applications

The INSPEC and Medline databases were searched with keywords: (i) data fusion and medical imaging, and (ii) multi modality imaging and medical imaging. The number of papers (including both conference and regular journal papers) published from 1969 to 2000 are given in Fig. 1. There were 127 and 81 papers published for data fusion and multimodality imaging in medical imaging, respectively. The bar plot clearly illustrates an increasing trend of publications for data fusion papers.

A snapshot of selected applications of data fusion papers in neurology, cardiology, oncology, and other is given in Table I.

## III. Case studies

In this section, case studies of image fusion techniques in oncology (data level fusion), microscopy, and ultrasound imaging (feature level and decision level fusion), and lesion placement in pallidotomy (data level fusion) are presented.

### III.I Image fusion in Oncology raises clinical value of PET [6]-[8]

Fluorine-18 deoxyglucose (FDG) PET is approved in the US for tumor detection and staging, diagnosis of recurrence, and follow up of various tumors. PET scans combined with CT and MRI in strategies of therapy planning, enable the visualization of functional and anatomic data, minimizing misinterpretations especially in the case of adjacent and very small tissue structures.

In the 700-bed Zentralklinik Bad Berka hospital in Germany, a whole body full ring PET scanner, is connected with a 1.5 Tesla MRI scanner, a multislice CT scanner, and a spiral CT scanner via the DICOM

standard. Images are transferred to a HERMES multimodality fusion station obtained from Nuclear Diagnostics. Automatic algorithms based on the mutual information criterion use PET transmission maps for image registration. The clinic carries on average 500 oncological fusion examinations per year.

Early detection of brain tumors is possible on MRI and CT but tumor grading remains a difficult task. FDG-PET can differentiate between high-grade (hypermetabolic) and low-grade (hypometabolic) tumors with high accuracy, however, it does not distinguish between low-grade tumors and some benign lesions. Other PET tracers, such as radiolabeled amino acids are useful in diagnosing low-grade tumors. FDG-PET is the most accurate noninvasive imaging modality for staging non-small-cell lung cancer. PET/CT fusion is also useful in planning radiation therapy of lung tumors. Moreover, FDG-PET is the most accurate procedure for the assessment of liver metastases in liver surgery, linked with its fusion of CT and MRI

The potential advances of image fusion in PET with cross-sectional 3D modalities can solve a number of oncology problems and has great potential for improving diagnostic accuracy. In addition, fusion of high resolution morphology and anatomy with biochemical and metabolic information will be essential to achieving optimal diagnostic accuracy. Image fusion will also play a major role in planning radiation therapy and radiosurgery.

Despite the many advantages of image fusion, relatively few hospitals use this technique at present. Limiting factors include: (i) cost intensive investment in hardware and software, (ii) time-consuming fusion procedures (10 to 45 min.), (iii) new 3D visualization techniques are needed to communicate the results to the clinicians, (iv) image registration and fusion tools are still evolving, and (v) CT, MRI, and PET data sets must be easily be transferred to one common imaging workstation. Finally, it is noted that objective and quantitative evaluation of spatial errors is an important task if image fusion is to gain clinical impact.

### III.II A Modular Neural Network System for the Analysis of Nuclei in Histopathological Sections [9]-[12]

The evaluation of immunocytochemically stained histopathological sections presents a complex problem due to many variations that are inherent in the methodology. This subsection describes a modular neural network system that is being used for the detection and classification of breast cancer nuclei named Biopsy Analysis Support System (BASS). The system is based on a modular architecture where the detection and classification stages are independent. Two

different methods for the detection of nuclei are being used: the one approach is based on a feed forward neural network (FNN) which uses a block-based singular value decomposition (SVD) of the image, to signal the likelihood of occurrence of nuclei. The other approach consists of a combination of a receptive field filter and a squashing function (RFS), adapting to local image statistics to decide on the presence of nuclei at any particular image location. The classification module of the system is based on a radial basis function neural network. A total of 57 images captured from 41 biopsy slides containing over 8300 nuclei were individually and independently marked by two experts. A five scale grading system, known as diagnostic index, was used to classify the nuclei staining intensities. The experts' mutual detection sensitivity (SS) and positive predictive value (PPV) were found to be 79% and 77% respectively. The overall joint performance of the FNN and RFS modules were 55% for SS and 82% for PPV. The classification module correctly classified 76% of all nuclei in an independent validation set containing 25 images. In conclusion, this study shows that the BASS system simulates the detection and grading strategies of human experts and it will enable the formulation of more efficient standardization criteria, which will in turn improve the assessment accuracy of histopathological sections.

### **III.III A Multi-feature Multi-classifier System for the Classification of Atherosclerotic Carotid Plaques [13]-[15]**

There are indications that the morphology of atherosclerotic carotid plaques, obtained by high-resolution ultrasound imaging, has prognostic implications. The objective of this work was to develop a computer-aided system that will facilitate the characterisation of carotid plaques for the identification of individuals with asymptomatic carotid stenosis at risk of stroke. A total of 230 plaque images were collected which were classified into two types: symptomatic because of ipsilateral hemispheric symptoms, or asymptomatic because they were not connected with ipsilateral hemispheric events. Ten different texture feature sets were extracted from the manually segmented plaque images using the following algorithms: first order statistics, spatial gray level dependence matrices, gray level difference statistics, neighbourhood gray tone difference matrix, statistical feature matrix, Laws texture energy measures, fractal dimension texture analysis, Fourier power spectrum and shape parameters. For the classification task a modular neural network composed of self-organizing map (SOM) classifiers, and combining techniques based on a confidence measure were used. Combining the classification results of the ten SOM

classifiers inputted with the ten feature sets improved the classification rate of the individual classifiers, reaching an average diagnostic yield of 73.1%. The same modular system was implemented using the statistical k-nearest neighbour (KNN) classifier. The combined diagnostic yield for the KNN system was 68.8%. The results of this work show that it is possible to identify a group of patients at risk of stroke based on texture features extracted from ultrasound images of carotid plaques. This group of patients can benefit from a carotid endarterectomy whereas other patients will be spared from an unnecessary operation.

### **III.IV Neural Network Analysis of Physiological Data for Lesion Placement in Pallidotomy [16]-[18]**

Current pharmacological therapy for Parkinson's disease loses its usefulness over time. Recently, pallidotomy, a surgical treatment for many of the symptoms of Parkinson's, has been re-investigated. This procedure requires localization of a small region within the globus pallidus. In this work, a simple electrophysiological analysis, used in conjunction with MRI imaging, provides excellent localization of the target derived from imaging studies alone. Investigation of more complex mathematical analysis may yield additional tools for localization. A new feature in this research is the after-lesion recordings. It has been proven to be valuable in re-assessing the condition of the patient. If residual activity is observed at the after-lesioning recording "session", additional lesions might be made, which might further alleviate the Parkinson symptoms.

## **IV. Concluding Remarks**

Concluding remarks are organized under two main categories: medical imaging issues in general, and data fusion. For the former, the following remarks are made for future researchers, motivated by Duncan and Ayche [19]:

1. Work in general must be developed and clearly motivated. Analysis should target both normal and pathology cases.
2. Medical image analysis tasks are taken in isolation, rather than considered together, i.e. segmentation and registration are pieces of the same underlying task of identifying structure.
3. Need to develop appropriate validation and evaluation approaches. There is a lack of availability of test data sets. Need for the formation of common datasets where algorithms can be compared and contrasted to.

4. The medical image analysis community must interact more with other communities, especially the medical physics one.

Some concluding remarks about data fusion follow (see also [2][20]):

1. Medical imaging teams have acquired now a better understanding of the use of image fusion methods.

2. There is a need for the development of tools for the better management of spatial information. Most of the current applications deal with 2D images, 3D applications are more complex (spatial information) and involve huge data sets.

3. Need for the establishment of a lexicon or terms of reference.

4. Data fusion should be seen as a framework, and not merely as a collection of tools and means (based on the data fusion remote sensing definition).

5. The introduction of the concept of data fusion should raise the awareness into the medical imaging community on the whole path ranging from the image acquisition to the decision, including the management, assessment and quality control.

Concluding, data fusion techniques need to be incorporated into CAD systems, including clinical data, thus enabling the early diagnosis, disease monitoring, better patient treatment, and the offering of a better service to the citizen.

**Table I** A snapshot of selected applications of data fusion papers in neurology, cardiology, oncology, and other

#### Neurology

- Neurosurgical monitoring and planning through pre-operative, intra-operative and post-operative assessment of therapeutic interventions through fusion of CT, PET, MRS and/or MRA/MRV with MRI [21].
- Image guided neurosurgery system based on preoperative MRI and intraoperative US to detect brain tissue deformation during craniotomy and monitor extent of lesion removal [22].
- MRI and SPECT fusion for the synthesis of high resolution 3D functional brain images for the monitoring of Alzheimer's disease [23].

#### Cardiology

- Quantitative measurements of coronary vessels in 3D and 4D based on X-ray angiography and IVUS. Facilitate volumetric and velocity measurements to monitor atherosclerosis [24][25].
- Tagged MRI and F18-FDG PET fusion system for the assessment of myocardial viability in patients with coronary heart disease [26].

#### Oncology

- MRI, CT, and PET fusion for tumor segmentation and localization for radiation therapy [27]

#### Other

- Fusion of US and X-ray images from the same volume of interest in breast pathologies [28].
- Endoscopic video fusion with CT and/or MRI in the visualization of structures and access paths in ENT surgery [29].

#### References

- [1] P.C. Barillot, J.C. Gee, L. Le Briquer, G. Le Goulher, "Inter- and intra-individual data fusion in medical imaging applied to the anatomical modeling of the human brain," *Traitement du Signal*, vol.11, no.6, pp.513-23, 1994.
- [2] L. Wald, "Some terms of reference in data fusion," *IEEE Trans. Geoscience and Remote Sensing*, vol. 37, no. 3, pp. 1190-1193, 1999.
- [3] M. Buchroithner, "Geodata interrelations: Inventory and structuring attempt of taxonomic diversity," in *Proc. 2<sup>nd</sup> Conf. Fusion of Earth Data: Merging Point Measurements, Raster Maps and Remotely Sensed Images*, 1998, pp. 11-15.
- [4] J.A. Benediktsson, "Introduction," Special Issue on Data Fusion, *IEEE Trans. Geoscience and Remote Sensing*, vol. 37, no. 3, pp. 1187, 1999.
- [5] C.S. Pattichis, and M.S. Pattichis, "Adaptive Neural Network Imaging in Medical Systems," in *Proc. of the 35<sup>th</sup> Asilomar Conf. on Signals, Systems, and Computers*, 2001.
- [6] C. Przetak, R.P. Baum, and P.J. Slomka, "Image fusion raises clinical value of PET," *Diagnostic Imaging Europe*, July/August, pp. 10-15, 2001.
- [7] P.J. Slomka, D. Dey, C. Przetak, and R. Baum, "Automated 3D spatial integration of F-18 FDG wholebody PET with CT," *J. Nucl. Med.*, vol. 41, pp. 59, 2000.
- [8] C. Przetak, R. Baum, A. Niesen, P.J. Slomka, et al. "Anatomometabolic image fusion of PET, CT and MRI," *Nuklearmedizin*, vol. 23, pp. 355-397, 2000.
- [9] F. Schnorrenberg, C.S. Pattichis, K. Kyriacou, M. Vassiliou, and C.N. Schizas, "Computer-aided Classification of Breast Cancer Nuclei," *Technology and Health Care*, vol. 4, no. 2, pp. 147-161, 1996.
- [10] F. Schnorrenberg, C.S. Pattichis, K.C. Kyriacou, and C.N. Schizas, "Computer-Aided Detection of Breast Cancer Nuclei," *IEEE Trans. Inf. Tech. Biom.*, vol. 1, no. 2, pp. 128-140, 1997.
- [11] F.S. Schnorrenberg, N. Tsapatsoulis, C.S. Pattichis, C.N. Schizas, S. Kollias, M. Vassiliou, A. Adamou, and K. Kyriacou, "Improved Detection of Breast Cancer Nuclei Using Modular Neural Networks," *IEEE Eng. in Med. and Biol. Mag.*, Special Issue on Classifying Patterns with Neural Networks, vol. 19, no. 1, pp. 48-63, 2000.
- [12] F. Schnorrenberg, C.S. Pattichis, et al., "Content-based Retrieval of Breast Cancer Biopsy Slides," *Technology and Health Care*, vol. 8, pp. 291-297, 2000.
- [13] C.I. Christodoulou, C.S. Pattichis, M. Pantziaris, T. Tegos, A. Nicolaides, T. Elatrozy, M. Sabetai, and S. Dhanjil, "Multi-feature texture analysis for the classification of carotid plaques," in *CD-ROM Proc. of the Int. Joint Conf. on Neural Networks, IJCNN '99*, Washington DC, 10-16 July, 1999.
- [14] C.I. Christodoulou, and C.S. Pattichis, "Medical diagnostic systems using ensembles of neural SOFM classifier," in *Proc of*

the 6th IEEE Int. Conf. on Electronics, Circuits and Systems, ICECS '99, Paphos, Cyprus, 1999, vol. I, pp. 109-112.

[15] C.I. Christodoulou, C.S. Pattichis, M. Pantziaris, and A. Nicolaides, "Texture based classification of atherosclerotic carotid plaques," submitted to *IEEE Trans. on Med. Imag.*, revised version in Nov. 2001.

[16] R.M. Lehman, E. Micheli-Tzanakou, Jian Zheng and J.L. Hamilton, "Electrophysiological recordings in pallidotomy localized to 3D stereoscopic imaging" *Stereotactic and Functional Neurosurgery*, vol. 72, pp. 185-191, 1999.

[17] R.M. Lehman, et al., "Comparison of 3-D- MR imaging with pre and post lesion recording in pallidotomy", *Acta Neurochirurgica*, vol. 142, pp. 319-328, 2000.

[18] R. M. Lehman, E. Micheli-Tzanakou, A. Medl, and J.L. Hamilton, "Quantitative on-line analysis of physiological data for lesion placement in pallidotomy", *Neurosurgery*, vol 729, pp. 1-15, 2001.

[19] J.S. Duncan, and N. Ayache, "Medical image analysis: Progress over two decades and the challenges ahead," *IEEE Trans. PAMI*, vol. 22, no. 1, pp. 85-102, 2000.

[20] I. Bloch, and H. Maitre, "Data fusion in 2D and 3D image processing: An overview," in *X Brazilian Symposium of Computer Graphic and Image Processing*, Ed. L. H. de Figueiredo, and M.L. Netto, Campos de lordao SP, Oct. 13-16, 1997, pp. 127-134.

[21] J.W. Haller, T. Ryken, M. Madsen, A. Edwards, L. Bolinger, and M.W. Vannier, "Multi-modality image fusion for image-guided neurosurgery," in *Proc. of 13th International Symposium on Computer Assisted Radiology and Surgery (CARS'99)*, Paris, France, June 1999.

[22] R.M. Comeau, A.F. Sadikot, A.F. Fenster, and T.M. Peters, "Intraoperative ultrasound for guidance and tissue shift correction in image-guided neurosurgery," *Medical Physics*, vol. 27, no. 4, pp. 787-800, April 2000.

[23] A.U. Colin and J-Y Boire, "MRI-SPECT fusion for the synthesis of high resolution 3D functional brain images: a preliminary study," *Computer Methods and Programs in Biomedicine*, vol. 60, no.2, pp. 107-116, Sept. 1999.

[24] M.E. Olszewski, R.M. Long, S.C. Mitchell, and M. Sonka, "Quantitative measurements in geometrically correct representations of coronary vessels in 3-D and 4-D," in *Proc. 4th IEEE Southwest Symposium on Image Analysis and Interpretation*, Austin, TX, April, 2000.

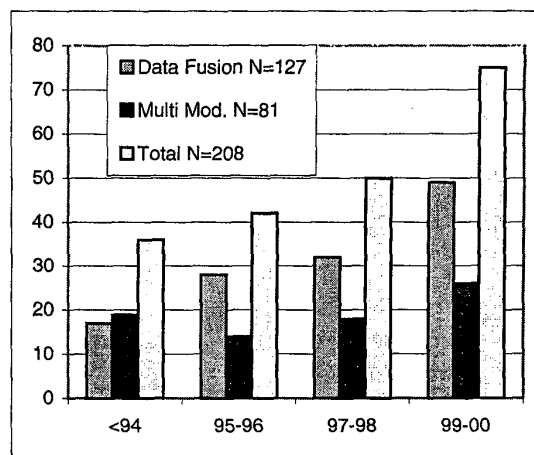
[25] A. Wahle, G.P.M. Prause, C. Von Birgelen, R. Erbel, and M. Sonka, " Fusion of angiography and intravascular ultrasound in vivo: establishing the absolute 3-D frame orientation," *IEEE Transactions on Biomedical Engineering*, vol. 46, no. 10, pp. 1176-1180, Oct. 1999.

[26] F. Belhloul, M. Janier, P. Croisille, C. Poirier, and A. Boudraa, "Automatic assessment of myocardial viability based on PET-MRI data fusion," in *Proc. of 20th International Conference of the IEEE Engineering in Medicine and Biology Society*, Hong Kong, China, Nov. 1998.

[27] R. Wasserman, R. Acharya, C. Sibata, and K.H. Shin, "A data fusion approach to tumor delineation," in *Proc. International Conference on Image Processing*, Washington, DC, Oct. 1995.

[28] A. Hernandez, O. Basset, I. Magnin, A. Bremond, and G. Gimenez, "Fusion of ultrasonic and radiographic images of the breast," in *Proc. of IEEE Ultrasonics Symposium*, San Antonio, TX, Nov. 1996.

[29] M.J. Truppe, W. Freysinger, A.R. Gunkel, and W.F. Thumfart, "Remote-guided surgical navigation in ENT surgery," in *Proc. of Medicine Meets Virtual Reality IV: Healthcare in the Information Age - Feature Tools for Transforming Medicine*, San Diego, CA, Jan. 1996.



**Fig. 1** Results of the INSPEC and Medline databases search with keywords: (i) data fusion and medical imaging, and (ii) multi modality imaging and medical imaging. For each entry, the first, second, and third bars show the hits for data fusion, multi modality, and their sum respectively.